

University of Texas at Tyler

## Scholar Works at UT Tyler

---

School of Medical and Biological Sciences  
Faculty Publications and Presentations

School of Medicine

---

Summer 6-7-2022

# A Deep Learning Framework for Earlier Prediction of Diabetic Retinopathy from Fundus Photographs

K. Gunasekaran

*Sri Indu College of Engineering and Technology*

R. Pitchai

*BV Raju Institute of Technology*

Gogineni K. Chaitanya

*Koneru Lakshmaiah Education Foundation*

D. Selvaraj

*Panimalar Engineering College*

S. Annie Sheryl

*See next page for additional authors*

Follow this and additional works at: [https://scholarworks.uttyler.edu/smbms\\_fac](https://scholarworks.uttyler.edu/smbms_fac)



Part of the [Medicine and Health Sciences Commons](#)

---

### Recommended Citation

Gunasekaran, K.; Pitchai, R.; Chaitanya, Gogineni K.; Selvaraj, D.; Sheryl, S. Annie; Almoallim, Hesham S.; Alharbi, Sulaiman Ali; Raghavan, S.S.; and Tesemma, Belachew Girma, "A Deep Learning Framework for Earlier Prediction of Diabetic Retinopathy from Fundus Photographs" (2022). *School of Medical and Biological Sciences Faculty Publications and Presentations*. Paper 5.

<http://hdl.handle.net/10950/4563>

This Article is brought to you for free and open access by the School of Medicine at Scholar Works at UT Tyler. It has been accepted for inclusion in School of Medical and Biological Sciences Faculty Publications and Presentations by an authorized administrator of Scholar Works at UT Tyler. For more information, please contact [tgullings@uttyler.edu](mailto:tgullings@uttyler.edu).



---

**Author**

K. Gunasekaran, R. Pitchai, Gogineni K. Chaitanya, D. Selvaraj, S. Annie Sheryl, Hesham S. Almoallim, Sulaiman Ali Alharbi, S.S. Raghavan, and Belachew Girma Tesemma

## Research Article

# A Deep Learning Framework for Earlier Prediction of Diabetic Retinopathy from Fundus Photographs

**K. Gunasekaran** <sup>1</sup>, **R. Pitchai**,<sup>2</sup> **Gogineni Krishna Chaitanya**,<sup>3</sup> **D. Selvaraj**,<sup>4</sup>  
**S. Annie Sheryl**,<sup>5</sup> **Hesham S. Almoallim**,<sup>6</sup> **Sulaiman Ali Alharbi**,<sup>7</sup> **S. S. Raghavan**,<sup>8</sup>  
**and Belachew Girma Tesemma** <sup>9</sup>

<sup>1</sup>Department of Computer Science and Engineering, Sri Indu College of Engineering and Technology, Hyderabad, Telangana 501510, India

<sup>2</sup>Department of Computer Science and Engineering, B V Raju Institute of Technology, Narsapur, Telangana 502313, India

<sup>3</sup>Department of Computer Science and Engineering, Koneru Lakshmaiah Education Foundation, Vaddeswaram, Andhra Pradesh 522502, India

<sup>4</sup>Department of Electronics and Communication Engineering, Panimalar Engineering College, Chennai, Tamil Nadu 600123, India

<sup>5</sup>Department of Computer Science and Engineering, Panimalar Institute of Technology, Chennai, Tamil Nadu 600123, India

<sup>6</sup>Department of Oral and Maxillofacial Surgery, College of Dentistry, King Saud University, PO Box-60169, Riyadh-11545, Saudi Arabia

<sup>7</sup>Department of Botany and Microbiology, College of Science, King Saud University, PO Box-2455, Riyadh-11451, Saudi Arabia

<sup>8</sup>Department of Microbiology, University of Texas Health and Science Center at Tyler, Tyler-75703, TX, USA

<sup>9</sup>Department of Mechanical Engineering, Mizan Tepi University, Ethiopia

Correspondence should be addressed to Belachew Girma Tesemma; belachewgt@mtu.edu.et

Received 5 March 2022; Revised 27 April 2022; Accepted 11 May 2022; Published 7 June 2022

Academic Editor: Yuvaraja Teekaraman

Copyright © 2022 K. Gunasekaran et al. This is an open access article distributed under the Creative Commons Attribution License, which permits unrestricted use, distribution, and reproduction in any medium, provided the original work is properly cited.

Diabetic patients can also be identified immediately utilizing retinopathy photos, but it is a challenging task. The blood veins visible in fundus photographs are used in several disease diagnosis approaches. We sought to replicate the findings published in implementation and verification of a deep learning approach for diabetic retinopathy identification in retinal fundus pictures. To address this issue, the suggested investigative study uses recurrent neural networks (RNN) to retrieve characteristics from deep networks. As a result, using computational approaches to identify certain disorders automatically might be a fantastic solution. We developed and tested several iterations of a deep learning framework to forecast the progression of diabetic retinopathy in diabetic individuals who have undergone teleretinal diabetic retinopathy assessment in a basic healthcare environment. A collection of one-field or three-field colour fundus pictures served as the input for both iterations. Utilizing the proposed DRNN methodology, advanced identification of the diabetic state was performed utilizing HE detected in an eye's blood vessel. This research demonstrates the difficulties in duplicating deep learning approach findings, as well as the necessity for more reproduction and replication research to verify deep learning techniques, particularly in the field of healthcare picture processing. This development investigates the utilization of several other Deep Neural Network Frameworks on photographs from the dataset after they have been treated to suitable image computation methods such as local average colour subtraction to assist in highlighting the germane characteristics from a funduscopy, thus, also enhancing the identification and assessment procedure of diabetic retinopathy and serving as a skilled guidelines framework for practitioners all over the globe.

## 1. Introduction

Diabetic retinopathy (DR) is characterised by severe vision impairment induced by the breakdown of blood vessels in the retinal area over time. Because DR gets increasingly difficult to treat as it progresses, early detection of the condition is critical. Earlier identification of DR is critical for medical prognosis, as it allows for therapy as well as further reduction of disorder progression. Early-stage DR identification could be divided into four distinct categories: moderate, mild, severe, and nonretinopathic. Numerous studies have used automatic DR assessment techniques, as well as these techniques offer various techniques for recognising intensity and categorising it into phases. The complexity of DR importance affects the therapy of DR plans for different individuals. Patients with no or light DR should get routine screening treatments, while those with serious or moderate DR should consider vitrectomy and laser therapy. The importance of immediate and appropriate management of the patient is determined by the difficulty degree. Since their ease of usage, suitability for acquisition, and improved visualization of lesions, fundus pictures are often used for DR screenings. The rise in diabetic patients has expanded the range of enhanced skilled ophthalmologists in terms of establishing the need for automated DR diagnostic procedures. Because the signs of possible DR are not visible to the human eye, a technique for automated earlier identification of DR is the most important necessity for studying the features and patterns of DR [1]. Computational visualization for diabetic retinopathy is essential to handle with, relieving ophthalmologists of the load of identifying individuals who need prompt eye care and treatments [2]. Several researchers have designed an automated DR diagnosis approach due to the high medical pertinence of DR arrangements for improved diagnosis.

Regular screenings for pathological diseases of the retinal [3, 4] could greatly aid in the avoidance of vision blindness. The most extensively utilized technique for earlier screenings and identification of disorders that cause blindness including diabetic retinopathy, age-related macular degeneration, glaucoma [5], stroke-induced, and hypertension alterations is fundus photography [6]. With the advancement of film-dependent photographic cameras to electronically imaging detectors, and also angiography, red-free imaging, hyperspectral imaging, stereo photography, and other techniques, fundus imaging has vastly enhanced, lowering inter as well as intraobserver reported variation. Retinal image processing [7] has also made a substantial contribution to this technical advancement [8]. Because fundus scanning is commonly utilized for first-phase deviation screenings, research focuses on (i) detecting and segmenting retinal features (fovea, optic disc, and vessels), (ii) abnormality segments, and (iii) picture clarity measurement to evaluate reported fitness. Retinal imaging has long been the gold standard for diagnosing DMO and DR [9, 10]. Nonetheless, assessing the intensity of retinopathy in people with diabetic is still mainly reliant on human assessment of retinal fundus pictures, which is difficult to do [11, 12]. As a result, an auto-

ated visual grading approach was essential in the earlier detection and assessment of these vision-threatening disorders. Current research [13] has shown that deep learning techniques can accurately diagnose DMO [14], probable glaucoma [15], and age-correlated macular degeneration [13, 15]. Numerous studies [16] have demonstrated that deep learning techniques may be used to provide expert-level assessments for retinal fundus imaging evaluation, particularly for diabetic retinopathy. These methods, on the other hand, provided significant results at the cost of increased time complexities. The consistency of these separate algorithms' categorization was quite poor because of the similar source picture dimensions. Furthermore, for an automated approach to be medically effective, it must be capable to categorise retinal fundus imaging flexibly using medically accepted intensity measures such as the diabetic macular edema disorder categories and international clinical diabetic retinopathy (ICDR) [17].

Currently, machine learning technologies offer a variety of computer-assisted options for automatic diabetic retinopathy categorization and assessment. Various characteristic extracting approaches are used by the DR identification to retrieve relevant information from the input fundus photographs. The characteristic extractor is done by hand, taking into account the changes in optical features of different lesions, and it must be resistant to diabetic retinopathy condition fluctuations [18]. The manually characteristic extracting approach for lesion identification might be implemented in automatic DR identification algorithms. It enables that diseases could be recognised both in isolation and in connection with several other illnesses, giving the ophthalmologist an alternative perspective for choice-making and more evaluation. The machine learning-dependent techniques can classify lesion categorization dependent on the selection boundaries as well as the activating parameters. These machine learning systems are not capable of adjusting these decision limitations by incorporating nonlinear variables, nor are they efficient for effective learning, limiting their capacities to do challenging jobs. Furthermore, component engineering, which is a time-consuming procedure that necessitates expert subject knowledge, might enhance machine learning techniques. To decrease information complexities and examine the result classified characteristics, subject professionals must have recognised the featured characteristics employed by machine learning approaches. Deep learning has grown as a step advance in automating the feature engineering process by efficiently incorporating component learning while learning the characteristics incrementally. Deep learning is regarded an end-to-end solution discovering strategy, as opposed to machine learning, which divides the procedure into separate portions and then joins them at the conclusion. In a variety of implementations, deep neural network (DNN) architectures have surpassed human-graded approaches. Convolutional neural networks (CNN) have, on the other side, made significant progress in picture identification as well as characterisation, and they are now being used in diabetic retinopathy diagnostic approaches.

An extended eye test is currently used to identify diabetic retinopathy. Eye dilating drops are injected into a patient's

eye to enlarge the pupil but also enable doctors to visualize the blood vessels in the eyes [19]. A particular dye is inserted, and images of the dye as it flows through blood vessels are obtained. The photos are utilized to look at the blood arteries in greater detail and detect any injured arteries or fluid leakage. These eye tests are quite successful; nevertheless, they expense \$250 or more in the United States for individuals without healthcare security, and they are frequently inaccessible in distant or underdeveloped regions of the globe. Computer eyesight has lately been suggested as a feasible substitute to a clinician's optical assessment in the identification of diabetic retinopathy. However one challenge, the Kaggle contest on diabetic retinopathy, attracted over 600 groups [20]. [21], on the other hand, use GoogLeNet and TensorFlow to offer an automatic identification of diabetic retinopathy. Various facets of featured extractor, from preprocessing to characteristic extraction, are discussed. [22] describe a convolution neural network-based categorization of diabetic retinopathy. The submitted research accomplishes four-class hierarchy categorization depending on the intensity of the disorder utilizing a self-gated soft-attention technique and a pretrained coarsely networks. The use of deep learning to diagnose diabetic retinopathy is also discussed [23]. Hardware-based methods have also been described in alternative method [24]. The study discusses the prospect of employing hardware to identify diabetic retinopathy utilizing a digital signal processor kit provided by Texas Instruments. High-resolution retina pictures captured with a fundus camera were used in these experiments. There have also been reports of attempts to identify retinopathy using photos acquired with lower expense cameras.

Diabetic retinopathy (DR) is a vasculopathy that damages the eye's tiny veins as well as being significant causes of avoidable blindness worldwide [17]. Between 40 and 45 percent of diabetes, individuals will develop diabetic retinopathy at several times in their lives; although, only around 50% of those with diabetic retinopathy are conscious of their illness [25]. Effective identification and management of DR are therefore critical in preventing this global epidemic of avoidable visual loss. Diabetic retinopathy is still common nowadays, and preventing it is difficult. Ophthalmologists commonly evaluate the existence and intensity of diabetic retinopathy by performing a detailed inspection of the fundus and analysing colour images. Because of the enormous number of diabetic people worldwide, this procedure is both costly and effort demanding [26]. Diabetic retinopathy intensity assessment and earlier disease identification are also rather subjective, with agreement statistics among trained professionals varied significantly, as preceding research has shown [27]. Moreover, 75 percent of diabetic retinopathy patients are living in poor regions, where there are insufficient specialists as well as detecting infrastructures [28]. Worldwide testing systems have been established to combat the spread of avoidable eye illnesses, but the prevalence of diabetic retinopathy is too high for certain programmes to effectively diagnose and treated retinopathy on an individualized foundation. As a result, millions of people around the globe continue to suffer from vision impairments

due to a lack of effective predicted diagnostic and eye treatment. Automatic systems for retinal disorder diagnosis from filtered colour fundus photographs have been offered in the previous to solve the shortcomings of existing diagnostics procedures [29]. A solution like this could relieve qualified experts' responsibilities by enabling untrained workers to effectively assess and analyse a large number of patients without relying on physicians. Prior techniques to automatic diabetic retinopathy identification, on the other hand, had severe disadvantages that make them unsuitable for huge scale assessments. Some of these techniques struggled to identify diabetic retinopathy reliably in huge level, heterogeneity real-world fundus information collections [30]. Furthermore, approaches generated from a single information collection might not generalise to fundus photographs acquired from various medical trials that utilize various kinds of fundus cameras, alternative techniques of eye dilatation, or both, limiting medical relevance in real-world processes [31]. Furthermore, most of these techniques rely on manually characteristic collection for diabetic retinopathy identification, with the goal of identifying prognostic anatomical components in the fundus, including the optical discs or blood vessels, using finely tailored characteristics. Even though such hand-tuned characteristics might execute effectively on single fundus information collections, by generalising to the initial sampling, they challenge to appropriately characterise diabetic retinopathy in fundus photos from various targeted groups. General characteristics including such HOG and SURF characteristics have been evaluated as a nonspecified technique for diabetic retinopathy identification, but these techniques seem to under suitable as well as gain knowledge weakening characteristics, making them incapable to characterise subtle variations in retinopathy intensity [32].

The following segments of this study are structured as follows: part 2 discusses literature review, and part 3 discusses the proposed mechanism for earlier diabetic retinopathy disorder prediction from fundus photographs using deep recurrent neural networks, as well as the framework's workflow in detail. Part 4 discusses the experimental findings, providing data and graphs comparing them to earlier research, and part 5 discusses the discussion. Finally, part 6 concludes the investigation.

## 2. Related Works

The goal of this study [33] was to see if aberrant mfERGs could forecast the establishment of diabetic retinopathy at the same retinal sites a year subsequently. Twelve months afterward the original assessment, eleven diabetic individuals with nonproliferative diabetic retinopathy (NPDR) as well as eleven diabetic individuals without retinopathy had one eye reevaluated. mfERGs from 103 retinal sites are collected at every period, whereas fundus pictures are obtained during one month of every observation. According to results from twenty age-matched regulated patients, localized mfERG implicitly durations were assessed and z-scores generated. Z-scores of two or higher for implied duration and -2 or lesser for intensity were used to establish mfERG abnormality

( $P \leq 0.023$ ). The connection among baseline aberrant  $z$ -scores as well as developing retinopathy at follow-up was investigated using mfERG  $z$ -scores as well as fundus images. After a decade, seven of the retina with NPDR established recurrent retinopathy. At foundation, 70 percent of the mfERGs in regions of developing retinopathy in these retina exhibited aberrant implicit durations. In comparison, just 24 percent of initial results in retinopathy-free areas were irregular. For comparison, just 24 percent of baseline reactions in retinopathy-free locations were irregular. The comparative probability of developing original retinopathy after a year was roughly 21 times higher in regions with irregular baseline mfERG implied moments (odds ratios = 31.4;  $P < 0.001$ ) than in regions with regular baseline mfERGs. Even though four of those eleven eyelids exhibited irregular approximate durations at baseline, eyes without prior retinopathy did not generate additional retinopathy during the research duration. In NPDR retina, mfERG implied durations neither were longer at follow-up than at foundation, though not in eyes without retinopathy nor regulate retina. The amplitudes of the mfERG exhibited no prognostic value. The advent of novel architectural indications of diabetic retinopathy is frequently preceded by localized operational irregularities of the retina evidenced by mfERG latencies. The localized areas of novel retinopathy identified a year afterward are predicted by these operational impairments.

Diabetic retinopathy monitoring is critical for averting disability [34], however, due to the growing number of diabetic individuals of every type, expanding up monitoring is difficult. The goal was to design a deep learning algorithm that could forecast the probability of diabetic retinopathy emerging within two years in individuals with diabetes. They developed but also tested several variations of a deep learning device to forecast the progression of diabetic retinopathy in diabetic individuals who have undergone teleretinal diabetic retinopathy monitoring in a general healthcare environment. A collection of one-field or three-field colour fundus pictures served as the inputs for both variations. The experimental collection had 5,75,431 eyes, 28,899 of which had known conclusions, while the existing 5,46,532 were utilized to supplement the training phase through multifunctional understanding. Verification was performed on one eye (chosen randomly) each individual from two databases: an internally verification collection of 3,678 eyes with established results (representing EyePACS, a teleretinal monitoring services in the United States) and an exterior verification collection of 2,345 eyes with established results. In the inner validating collection, the three-field deep learning algorithm had a region around the receiver operational characteristics curves (AUC) of 0.79 (95 percent CI 0.77 – 0.81). The one-field deep learning algorithm scored 0.70 (0.67–0.74) on the exterior validity dataset, which solely featured one-field colour fundus pictures. The AUC of accessible hazard variables in the inner validating collection was 0.72 (0.68–0.76), but after merging the deep learning algorithm with these hazard variables, it increased to 0.81 (0.77–0.84) ( $P < 0.0001$ ). After the incorporation of the deep learning algorithm to accessible hazard variables, the associated AUC enhanced from 0.62 (0.58–0.66) to 0.71 (0.68–

0.75;  $P < 0.0001$ ) in the externally verification collection. The deep learning algorithms used colour fundus pictures to forecast diabetic retinopathy progression, as well as the algorithms were independently of and better relevant than existing hazard indicators. A hazard categorization technique like this could assist to improve monitoring durations whereas lowering expenses and increasing vision-associated results.

To design and evaluate a prototype predicated on multifocal electroretinogram (mfERG) [35] implied durations with candidate diabetes hazard variables to forecast the establishment of localized areas of non-proliferative diabetic retinopathy (NPDR). While in an initially and twelve-month follow-up assessment, mfERGs and fundus pictures were taken from 28 diabetes individuals' eyes. Utilizing a template stretching technique, mfERG implied timings were determined at 103 sites, and a  $z$ -score was produced in contrast to twenty age-matched normal participants. Thirty-five non-overlapping retinal regions were created by combining 2 to 3 nearby stimulation areas and assigning the highest  $z$ -score within every region to every region. Regions with early retinopathy were omitted from additional investigation. Depending on the mfERG implied duration  $z$ -score for the region as well as additional possible diabetes hazard variables established before the initial appointment, the possibility that novel retinopathy could establish in the remainder regions by the follow-up assessment were modelled. The prediction algorithm was evaluated using information from four recently untreated diabetes participants as well as the other vision of 8 preceding individuals throughout their following year follow-up. Within the year, 11 of the 12 NPDR eyes and 1 of the 16 eyes without original retinopathy acquired novel retinopathy. When taking into considerations the connection between regions inside every eye, a prediction framework was created using the parameters mfERG implied period, diabetes length, and retinopathy presence (no retinopathy or NPDR), but also blood glucose levels at baseline. This multivariate prototype's region underneath the receiver operational characteristics (ROC) curves are 0.90 ( $P < 0.001$ ). The testing results confirmed that the prediction framework has anticipated sensitivities of 86 percent as well as a selectivity of 84 percent. A multivariate approach could accurately forecast the progression of diabetic retinopathy during the course of a year. The algorithm was able to predict the particular areas of prospective retinopathy thanks to the incorporation of localized mfERG implied timings.

Diabetic patients can also be identified earlier utilizing retinopathy photos [36], but it is a challenging task. The blood veins visible in fundus photographs are used in several disease diagnosis approaches. Several traditional approaches are unable to discover hard executes (HE) in retinopathy photographs, which are utilized to assess the complexity of diabetes. To address this issue, the suggested study incorporates deep networking into convolutional neural networks to retrieve elements (CNN). On moderate diabetic retinopathy pictures, the microaneurysm can be detected in the initial phases of the shift from healthy to sick conditions. The confused matrices detecting outcomes can be used to classify the

seriousness of the diabetic situation. Utilizing the suggested convolutional neural network structure, earlier identification of the diabetic state was performed utilizing HE detected in an eye's blood artery. A person's diabetes state can also be detected using the suggested structure. This paper proves that the suggested method's effectiveness is greater than that of existing conventional detecting techniques. The primary flaws are expanded to encompass real-time photos from the unprocessed reality. Additional research is required for actual-world medical scenarios, and the device must be reliable. Similar techniques may allow medical providers to engage with more individuals in order to identify them more quickly. As a result, incorporating massive databases into deep learning algorithms would become increasingly important in the coming years.

Utilizing the Inception-v3 networks and a deep transferring learned technique [10], they were able to identify diabetic retinopathy (DR) in retinal fundus pictures automatically. A maximum of 19,233 colour arithmetic pictures of the eye fundus were acquired prospectively from 5,278 elderly individuals presented for DR assessment. According to the International Clinical Diabetic Retinopathy intensity dimension, the 8,816 photographs transmitted picture performance evaluation and were evaluated as no evident diabetic retinopathy (1,374 pictures), proliferative diabetic retinopathy (PDR) (936 pictures) moderate NPDR (2,370 pictures), mild nonproliferative diabetic retinopathy (NPDR) (2,152 pictures), and severe NPDR (1,984 pictures) by eight retinal researchers. Following picture preprocessing, 7,935 DR photos from the following classifications were chosen as a training phase database, with the remaining photographs serving as a validating database. To evaluate and improve the approach, they used a 10-fold cross-validation technique. They also used the publically available Messidor-2 datasets to evaluate the algorithm's effectiveness. They also calculated predicted efficiency, sensitivities, specificity, region underneath the receiver operational characteristics curves (AUC), and  $j$  score to distinguish among no referrals (moderate NPDR or no evident diabetic retinopathy) but also referrals (severe NPDR, PDR, and moderate NPDR). On the individual testing database, the suggested method had a categorization precision of 93.49 percent (95 percent confidence timeframe (CI), 93.13 percent–93.85 percent), with a sensitivity of 96.93 percent (95 percent CI, 96.35 percent–97.51 percent) and a specificity of 93.45 percent (95 percent CI, 93.12 percent–93.79 percent) and an AUC of 0.9905 (95 percent CI). The finest prototype has a  $j$  score of 0.919, whereas the three researchers had  $j$  scores of 0.906, 0.931, and 0.914, respectively. This method can help provide referral recommendations for additional examination and therapy with great reliability by mechanically detecting diabetic retinopathy with great specificity, sensitivities, and precision.

Diabetic retinopathy (DR) continues to develop globally [37], and it is still the major source of visual losses. They present a deep learning (DL) system for predicting DR development utilizing colour fundus photos (CFPs) collected in a solitary session from an individual with DR as inputs. The suggested deep learning prototypes were instructed against diabetic retinopathy intensity rating evaluated after

6, 12, and 24 months from the initial visit by masked, well-trained, human learning centre graders, and then were developed to anticipate prospective DR advancement, characterised as 2-step worsening on the initial therapy diabetic retinopathy intensity scale. One of these algorithms' effectiveness (forecast at monthly twelve) contributed in a region over the curves of 0.79. These findings highlight the significance of the predictive signals seen in the peripheral retina regions, which is not frequently gathered for DR evaluations, as well as the significance of microvascular anomalies. Their results demonstrate that using CFPs from a single session, it is possible to forecast prospective diabetic retinopathy advancement. Such an approach may allow earlier detection and referrals to a retinal expert for more regular observing and perhaps discussion of earlier interventions if it is subsequently developed on greater and much more diversified databases. Furthermore, it has the potential to increase patient recruiting for DR medical investigations.

Diabetic retinopathy (DR), also known as retinal vascular disorder, is the most common consequence of diabetics that results to blindness [38]. Frequent screenings for earlier diagnosis of DR disorder is seen as a time-consuming and resource-intensive endeavour. As a result, the use of computing techniques to execute automated identification of DR disorders is a fantastic answer. The existence of an irregularity in fundus images (FI) can be determined more reliably using an automated approach, although the categorization procedure is ineffective. Furthermore, several studies have been conducted to examine textural discriminating capability in fundus images in order to detect healthier photographs. Furthermore, because of the great dimensions, the featured extractor (FE) procedure did not work effectively. As a result, the machine learning bagging ensemble classifier (ML-BEC) was created to uncover retinal characteristics for DR disorder diagnostics and earlier identification utilizing machine learning with ensemble categorization. There are two phases to the machine learning bagging ensemble classifier technique. The candidate components are extracted from retinal photographs in the initial phase of the ML-BEC approach (RI). Optic nerve, optic disc size, neuroretinal rim, blood vessels, thickness, neural tissue, and variation are examples of possible items or traits for DR illness identification. The ensemble classification outperforms individual categorization algorithms in terms of classification effectiveness. Studies show that the machine learning-oriented ensemble classifier is effective at decreasing DR identification duration even further.

Deep learning is a collection of computing approaches that enable an approach to program itself through learning from a huge number of instances that illustrate the intended behaviour [39], eliminating the requirement for specified instructions. Additional testing and verification of these approaches in clinical scanning is required. To use deep learning to develop an approach for detecting diabetic macular edema and diabetic retinopathy in retinal fundus pictures automatically. A deep convolutional neural network, a form of neural network optimised for picture categorization, was instructed utilizing a retrospective advancement knowledge collection of 128,175 retinal photographs that

were evaluated 3 to 7 times by a panel of 54 United States licenced ophthalmology and ophthalmologists senior for diabetic retinopathy, photograph gradability, and diabetic macular edema. The resulting methodology was tested on two distinct information collections, each assessed by at minimum seven board-certified ophthalmologists in the United States with significant intragrader accuracy. Method is with deep learning training. The method's specificity and sensitivity for identifying referable diabetic retinopathy (RDR), characterised as moderately to severe diabetic retinopathy, referable diabetic macular edema, or all, were calculated using the reference standards of the ophthalmologist panel's overall conclusion. The technique was tested at two different operational positions from the experimental dataset, one for higher selectivity and the alternative for maximum sensitivities. The EyePACS-1 information collection included 9963 photographs from 4997 patients (average age, 54.4 years; 62.2 percent women; RDR prevalence, 683/8878 comprehensively gradable photographs (7.8%)); the Messidor-2 information collection included 1748 photographs from 874 patients (average age, 57.6 years; 42.6 percent women; RDR prevalence, 254/1745 comprehensively changeable photographs (14.6 percent)). EyePACS-1 had sensitivities of 97.5 percent and a specificity of 93.4 percent, while Messidor-2 had sensitivities of 96.1 percent and a specificity of 93.9 percent utilizing a second operational location with higher sensitivities in the developmental collection. A system depending on deep machine learning has good specificity and sensitivity for diagnosing related directly diabetic retinopathy in this study of retinal fundus pictures from persons with diabetics. More investigation is needed to see if this method can be used in the medical context and if it can enhance healthcare and performance when contrasted to existing ophthalmologic evaluations.

Grading diabetic retinopathy (DR) is critical for establishing appropriate therapy and follow-up for patients, but the monitoring procedure could be time-consuming and error-prone [40]. Although deep learning algorithms have shown promise as computer-aided diagnostic (CAD) devices, their black-box characteristic makes medical use difficult. They offer DR|GRADUATE, a unique deep learning oriented DR classification computer-aided diagnostic approach that backs up its conclusion with a clinically understandable explanation and an estimate of how imprecise the forecast is, and enabling the ophthalmologist to assess how much that choice can be believed. They created DR|GRADUATE with the linear character of the DR graded challenge in mind. DR|GRADUATE can deduce a photograph grade coupled with an explanatory mapping and a predictive uncertainty despite getting trained simply on image-wise labelling thanks to a unique Gaussian-sampling technique based on a multiple instance learning methodology. The Kaggle DR detecting training phase collection was used to learn DR|GRADUATE, which was then tested on a variety of databases. In five distinct databases, a quadratic-weighted Cohen's kappa ( $\kappa$ ) of 0.71 to 0.84 was reached in DR scoring. They demonstrate that photographs with lower forecasting unpredictability have higher scores, implying that this unpredictability is a meaningful measurement of

forecasting accuracy. Furthermore, poor photograph clarity is often related to increased uncertainty, demonstrating that photographs unfit for diagnostic do really result in fewer reliable predictions. Furthermore, studies on unknown clinical picture information categories imply that DR|GRADUATE can identify outliers. In overall, the attentiveness mappings show areas of concern for diagnostics. These findings demonstrate that DR|GRADUATE has a lot of possibilities as a second opinion method for DR intensity rating.

Replication researches are necessary for the verification of novel methodologies [41], as well as maintaining the highest requirements of scientific publishing and putting the findings into practise. In implementation and verification of a deep learning system for diagnosis of diabetic retinopathy in retinal fundus pictures, they sought to reproduce the primary strategy. They reimplemented the function using publically accessible information collections because the original information was not accessible. For training phase, the primary research utilized nonpublic fundus photos from EyePACS and three Indian institutions. They utilized a separate KaggleEyePACS information sets. The method's effectiveness was evaluated using the Messidor-2 benchmarking information collection in the previous research. The information sample was the similar for each of them. Ophthalmologists regraded every photo for diabetic retinopathy, macular edema, and photograph gradability in the initial research. For the huge databases, there was just one diabetic retinopathy grading each photograph, therefore, they graded the images manually. Hypervariable settings were not provided in the primary research. Most of these, however, were subsequently posted. Because of a lack of information in the procedure descriptions, they were unable to reproduce the actual work. Their greatest replicating attempt resulting in an approach that was unable to replicate the actual research's findings. The region underneath the receiver operational characteristics curves (AUC) of the method was 0.94 on the KaggleEyePACS testing collection and 0.80 on Messidor-2, which fell short of the previous article's estimated AUC of 0.99 on both testing collections. This could be due to the usage of a singular grading every photograph, alternative datasets, or alternative hyper variables that are not provided. They used a variety of normalisation strategies and discovered that training the photos to a [1] region produced the optimum outcomes for this replicating. This work demonstrates the difficulties in reproducing deep learning techniques, as well as the necessity for more replicate experiments to verify deep learning methodologies, particularly in the field of clinical picture processing.

### 3. Proposed Methodology

Depending on an available DR database, Figure 1 depicts the suggested DRNN framework for predicting DR diagnostic from numerous hazard variables. Information preprocessing weeded out irrelevant and conflicting information. Data normalisation was performed throughout the preprocessing step by resampling real-valued numerical variables to [0, 1]. Average and median were used to fill in lacking numbers in the numerical and conceptual properties, correspondingly.



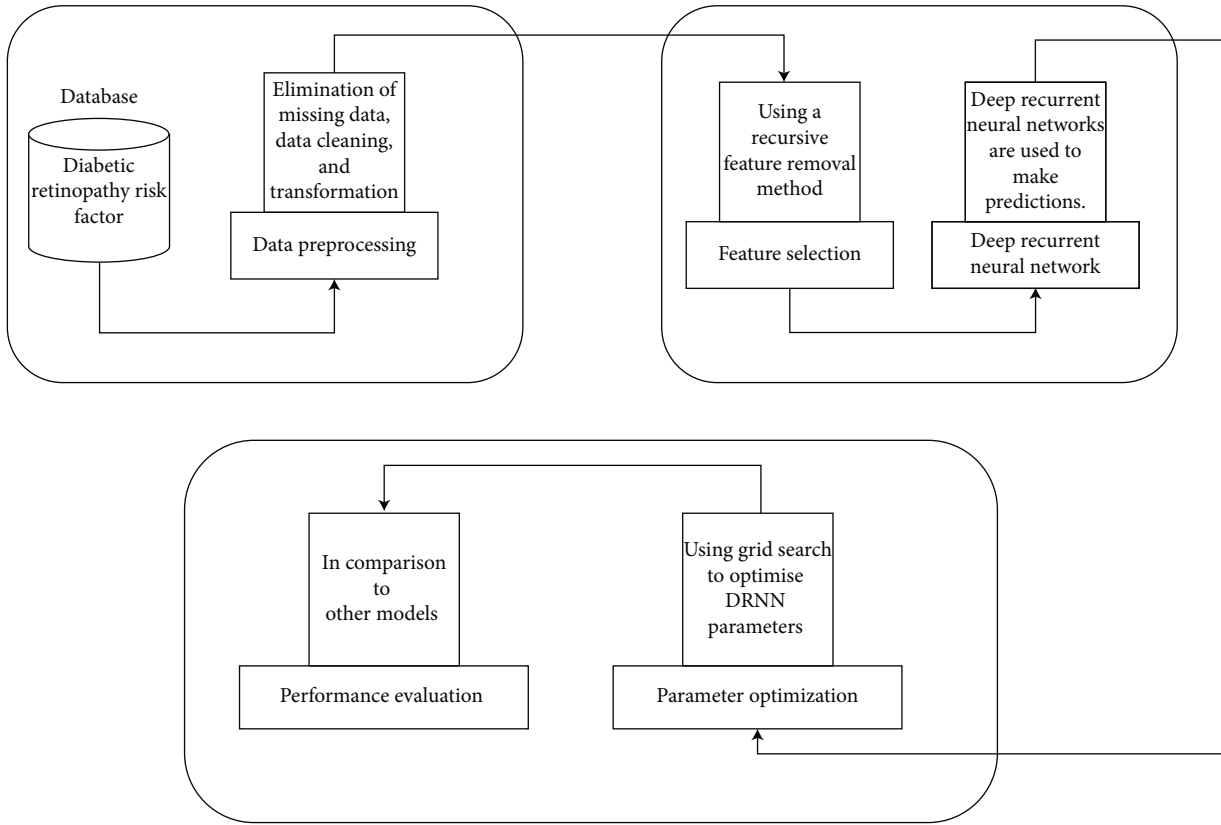


FIGURE 1: A deep recurrent neural network model for predicting diabetic retinopathy (DR) has been presented.

Moreover, utilizing the grid searching technique to optimise the modelling hypermeasurement and thus enhance DRNN effectiveness, RFE was used to eliminate unnecessary characteristics, and a DRNN dependent forecast was constructed. The proposed technique’s effectiveness was compared to that of other best-practise machine learning methods from earlier research. For the proposed and comparative machine learning algorithms, we employed stratification 10-fold cross-validation (CV), a version of  $k$ -fold CV. In  $k$ -fold CV, the database is divided into  $k$  equal-sized subsets, and the cases for every subset or folding are chosen at randomness. Every subset is utilized for testing, with the remaining being utilized for training phase.

The prototype is assessed  $k$  times, with every subset serving as the testing sample just once. In stratified  $k$ -fold cross-validation, on the other hand, every subset is stratified to have roughly the similar proportion of category categories as the existing database. The variations among the estimations are decreased by this technique, and the median error estimation is more acceptable. Moreover, our sample is unbalanced, with 45 percent of the participants being diagnosed with DR. Stratified  $k$ -fold CV is typically deemed better to normal CV, especially for imbalanced collections, according to a recent research [42]. The information came from 150 diabetic patients and included established hazard characteristics for food ulcer histories, nephropathy, peripheral vessel disease (PVD), neuropathy, cardiovascular disease (CVD), the dawn impact, and diabetic retinopathy (DR). The database previously comprised of 30 pieces of

information acquired from diabetes individuals. Table 1 shows the 11 possibly diabetic retinopathy applicable hazard variables after removing unnecessary characteristics. Whenever the patient had problematic symptoms with a background of lasers or surgery treatment, the classification designation (retinopathy) was provided. Our article’s goal was to determine whether or not a diabetic patient would establish diabetic retinopathy (DR) in the coming years.

**3.1. Deep Recurrent Neural Network Algorithms.** Deep learning is a more subsequently established machine learning approach that uses several levels of ANN to emulate the human brain [43]. Because there are no clear parameters for distinguishing among shallow and deep levels at the depth criterion, the latter is commonly regarded as containing numerous concealed levels (Figure 2). A  $(L + 1)$  layer perceptron has  $N$  input units,  $O$  output units, and multiple so-called unknown modules, as shown in Figure 2. An inputs level, an output layer, and  $L$  hidden layers make up a multilayer perceptron. The result is calculated by the  $i$ th units in layer  $l$ .

$$y_i^{(l)} = f\left(c_i^{(l)}\right) \text{ with } c_i^{(l)} = \sum_{k=1}^{m^{(l-1)}} w_{i,k}^{(l)} y_k^{(l-1)} + w_{i,0}^{(l)}, \quad (1)$$

where  $w_{i,k}^{(l)}$  signifies the weighed link from the  $k^{\text{th}}$  modules in level  $(l - 1)$  to the  $i^{\text{th}}$  elements in level  $l$ , and  $w_{i,0}^{(l)}$  could be

TABLE 1: Datasets on diabetic retinopathy.

Explanation	Feature	Range	Category
Subject's diabetes duration (y)	DM	0–30	Numeric
The average blood glucose levels of the patient during the previous three months (mg/dL)	A1c	6.5–13.3	Numeric
Subject's age (y)	Age	16–79	Numeric
Subject's body mass index	BMI	18–41	Numeric
High-density lipoprotein levels (mg/dL) of the subject	HDL	20–62	Numeric
Low-density lipoprotein concentration (mg/dL) of the individual	LDL	36–267	Numeric
The diastolic blood pressure of the individual (mmHg)	Dias BP	60–120	Numeric
Triglyceride levels (mg/dL) of the individual	TG	74–756	Numeric
Fasting blood sugar levels (mg/dL) of the individual	FBS	80–510	Numeric
The systolic blood pressure of the individual (mmHg)	Sys BP	105–180	Numeric
The condition of the individual's retinopathy	Retinopathy (class)	0 = no (91) 1 = yes (42)	Categorical

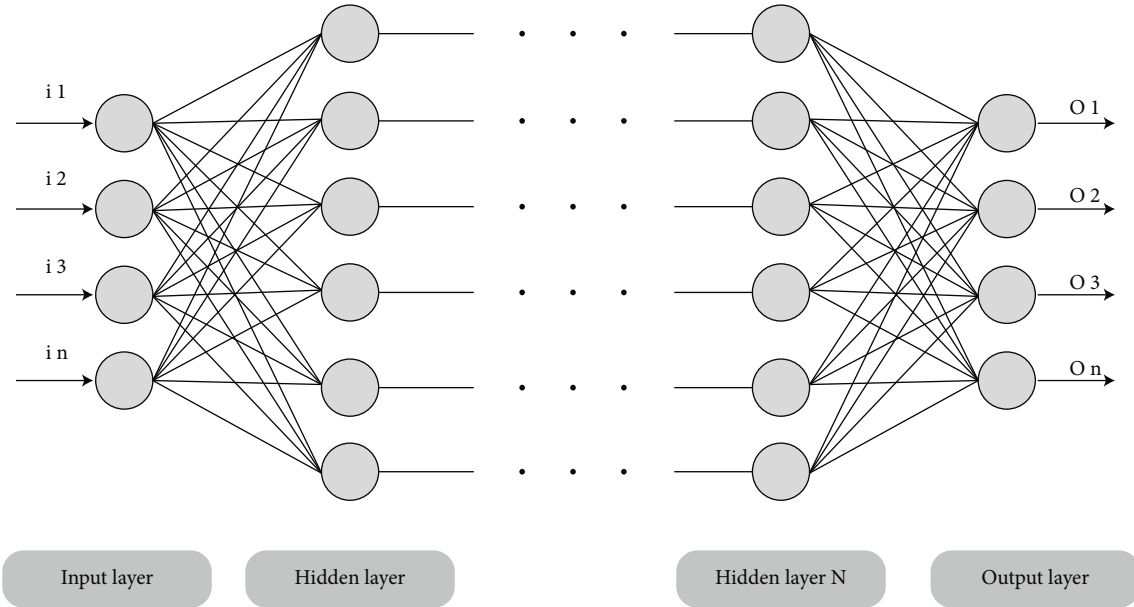


FIGURE 2: Deep neural networks' fundamental framework.

seen as an exterior input to the unit and is called bias. Furthermore,  $N = m^0$  and  $O = m^{(L+1)}$  represent the number of elements in level  $l$ , whereas  $m^{(l)}$  represents the number of elements in level  $l$ . By providing a false component  $y_0^l := 1$  in every level, the biases could be treated as a weight.

$$c_i^{(l)} = \sum_{k=0}^{m^{(l-1)}} w_{i,k}^{(l)} y_k^{(l-1)}. \quad (2)$$

While  $c^l$ ,  $w^l$ , and  $y^{(l-1)}$  signify the matching vectors and matrices representing the real values  $c_i^{(l)}$ , the weighted  $w_{i,k}^{(l)}$ , and the results  $y_k^{(l-1)}$ . The multilayered perceptron as a whole has the following component:

$$y(.,w): \mathbb{R}^N \longrightarrow \mathbb{R}^O, x \longrightarrow y(x, w). \quad (3)$$

The DRNN (deep recurrent neural network) was constructed in this chapter. Every storage blocks in the recurring hidden layers comprised computing elements in a structure. The storage blocks included storage compartments with self-connections that stored the program's temporally status, as well as a multiplicative units termed "gates" that regulated the stream of data into the units. The existing framework had input gates and an output gates. The tanh and sigmoid functions were used to estimate the input gates, which regulated the stream of knowledge and activations into the cells. For the remainder of the networks, the output gates regulated the output flows of the unit, and the activating functional was derived utilizing the tanh and sigmoid functions. The inner status of the forgetting gate gradually performs validation when connecting inputs to the unit via the cell's self-recurrent link; as a result, the cell's knowledge is forgotten or restored [44]. The logistic algorithm was utilized to compute these gates.

**3.2. Optical Coherence Tomography (OCT) and Fundus Photographs.** Optical coherence tomography (OCT) is a volumetric scanning technology that detects the absorption of infrared radiation in biological tissues with a spatial accuracy of lower than  $5\ \mu\text{m}$  in three dimensions. An infrared photograph of the individual's fundus as well as a coregistered stacking of optical coherence tomography pictures provides a 3-dimensional perspective of the person's retinal morphology in a standard optical coherence tomography evaluation. This tomographic data is utilized to create retinal thickness mapping that offer essential data to retinal specialists but also ophthalmologists concerning diseases and anomalies in their individuals' retina. Differences in these scanning modalities are crucial for differentiating and categorising different types of macular disorders. The fundus and optical coherence tomography pairing are frequently acquired at specialised eye clinics nowadays because of the greater tomographic picture offered by optical coherence tomography; thus, this knowledge is available in enormous quantities.

**3.3. Collection of Tissue Identification Data.** The tissue segmented information collection included 1000 optical coherence tomography (OCT) B-scans, with 866 of them coming from the LMU eye clinic's conventional Spectralis OCT instrument, in which every scanning was chosen from separate patients and labelled by a group of four clinicians utilizing the openly sourced application LabelMe (v3.16.1). In particular, 150 publically accessible OCT pictures with descriptions were gathered from the Duke Enterprises Information Consolidated Knowledge Explorers as well as [45], correspondingly. The optical coherence tomographies from the Duke repository were acquired utilizing a normal Spectralis OCT, whereas [45] utilized a Topcon 3-dimensional optical coherence tomography 1000 equipment. With no patient overlapping, the photos were randomized and divided into 634 training, 211 validation, and 155 testing photographs.

**3.4. Data Set for Predicting Thickness.** The fundus and optical coherence tomography pairings of 110,876 eyes from 19,884 distinct individuals were obtained from the LMU eye health centre information collection. After deleting inaccurate and low-quality data, the data set consisted of 85 and eight thousand seven hundred thirteen optical coherence tomography samples from 18,701 individuals. For the density mapping calculations, these were separated, overlaid, and continuously approximated. The 85,713 filtering fundus and thicknesses map pairings were then used to train and assess the deep neural network.

**3.5. Data Set for Screening Assessment.** The screened assessment information collection includes optical coherence tomography photographs from 261 distinct individuals, which were chosen at random based on the preceding requirements: every individual could only have one eye contained. Many diagnoses were also accompanied by optical coherence tomography images. The results of 50% of the scanning revealed no pathological alterations, while the other 50% revealed abnormalities. Because thickness is a

more frequent trait, it was highly illustrated in the scanning. The information collection was then examined for accurate alignments by one clinician, as well as the appropriate classification was determined.

**3.6. Information Collection for Diabetic Retinopathy on Kaggle.** The accessible diabetic retinopathy information collection that was utilized for transferring knowledge came from a prior Kaggle competition. For training phase, 35,126 colour fundus photos were used, and 10,906 photographs from the available testing phases were used for assessment. The photos were divided into five phases of diabetic retinopathy: initial stage there is no retinopathy, mild retinopathy, moderate retinopathy, severe retinopathy, and final stage for proliferative retinopathy.

**3.7. The Algorithm for Tissue Segmentation.** A U-net design neurological framework was utilized for tissue fragmentation, as described in [46], with batch normalisation and rectified linear component authorizations after every convolution layers, and enhanced drop-out after every max pooling surface, as described. Conventional trained settings as well as preprocessing were employed since thicknesses knowledge can be simply extracted from the OCT modalities.

**3.8. Diabetic Retinopathy Risk Assessment.** The following is a comparison of multifocal electroretinograms (mfERGs) and grading fundus photos in this study. To begin, answers from existing retinopathy regions were ruled out. The remainder early reactions were grouped into "of multifocal electroretinograms regions," which consisted of three to seven contiguous stimulating areas, regardless of where additional retinopathy occurred subsequently. With a centre component, these nonoverlapping of multifocal electroretinogram regions were built symmetrically. This procedure began in the uppermost left region of the stimulation arrays and continued diagonally through successive rows to the bottom right region. The central component was selected to accommodate the greatest amount of components every region. The number of pieces per zone ranges from three to seven even though to the variable geometry of the total stimulation course's perimeter, as well as changes in the positions of previous a retinopathy zones. Depending on whether at minimum one mfERG  $z$ -score in that region exceeds 2.0, every mfERG region was then classed as regular or irregular. The darker section is an existing retinopathy section that is not included in the study, and the stimulating retinal surface is separated into 17 multifocal electroretinogram regions (3 aberrant and 14 regular) with strong dark outlines separating them. Recurrent retinopathy is found in three of the regions, as illustrated by the grey shading, with two (77.8 percent) occurring in aberrant mfERG areas but one (8 percent) occurring in the 15 typical multifocal electroretinogram regions. On the foundation of baseline implicitly temporal  $z$ -scores, 74 (45.7%) of the multifocal electroretinogram regions in the 15 NPDR eyes were classified as aberrant (Table 2). Following a year, 33 (46%) of the 65 anomalous mfERG regions had developed recurrent retinopathy,

TABLE 2: Initial aberrant mfERG can forecast recurrent retinopathy; inferred time.

Early mfERG region	Follow-up on the advancement of retinopathy		Total
	Yes	No	
Irregular	33	52	74
Regular	3	228	220
Total	35	269	293

Odds ratio = 3.14;  $P < 0.002$

compared to just 3 (2percent) of the 120 healthy mfERG regions. As a result, abnormal mfERG zones were 25 percent more probable than regular mfERG regions to acquire retinopathy within a year. The risk proportion for the formation of novel retinopathy in the areas with aberrant background mfERG inference durations is 31.4 ( $P < 0.002$ ). Although the threshold of implicitly timing abnormalities was more conservatively established as a  $z$ -score of 3 or higher ( $P \leq 0.0015$ ), anomalous mfERG regions are nearly 9 times greater probable than regular mfERG regions to acquire recurrent retinopathy (odds ratio = 17.7;  $P < 0.001$ ). The intensity of a reaction does not anticipate the onset of diabetic retinopathy. There is no variation in the establishment of subsequent retinopathy among irregular and regular mfERG regions whenever beginning reaction magnitude is utilized to determine anomalous mfERG regions (20 percent vs. 15 percent; odds ratios = 2.4;  $P = 0.82$ ).

**3.9. Training Information for Retinal Photographs.** The information comprises of 50 photos collected from the Gold Standard Dataset, which is open to the community. There are 20 photos of healthful individuals, 20 photographs of diabetic retinopathy patients, and 20 photographs of glaucoma patients in the dataset. This information was compiled by a collection of retinal photograph processing professionals and physicians from the cooperating ophthalmology centres.

**3.10. Fundus Photograph Preprocessing.** Prior to characteristic relevancy assessment, the fundus photograph was pre-processed. To reduce the distortion in the picture, averaged filtration was used. The resulting picture's green channels ( $G$ ) were segregated. The picture's green channels ( $G$ ) were subjected to histogram equalisation ( $H$ ). The  $H$  and  $G$  pictures were used to obtain parameters. On every picture, 32 measures were taken. Statistically assessments, grey-level cooccurrence matrix (GLCM) dependent estimations, and histogram oriented dimensions were among the methods used. The observations are utilized as training phase input collection properties. The information for those 30 observations is continual. The property (result) is the category element, which has the values  $g$  (glaucoma),  $h$  (healthy), or  $dr$  (diabetic retinopathy). The characteristics and their acronyms are listed in Table 3.

TABLE 3: Fundus photograph assessments.

Name of the element	Formula
Minimum $H$ intensity ( $H$ min)	$\min (H(i, j))$
Maximum $H$ intensity ( $H$ max)	$\max (H(i, j))$
Standard deviation (std)	$\sqrt{\frac{1}{n} \sum_{i=1}^n (H(i) - \text{mean})^2}$
Minimum $G$ intensity ( $G$ min)	$\min (g(i, j))$
Maximum $G$ intensity ( $g$ max)	$\max (G(i, j))$
Variance (var)	(Standard deviation) <sup>2</sup>
Mean	$\frac{1}{M * N} \sum_{i=1}^N \sum_{j=1}^M H(i, j)$
Entropy (ent)	$-\sum_{i=1}^n H(i) * \log_2 H(i)$

## 4. Experimental Result

**4.1. Training and Testing Dataset.** Healthy, moderate diabetic retinopathy, medium diabetic retinopathy, serious diabetic retinopathy, and proliferative diabetic retinopathy are the five types of diabetic retinopathy (Table 4). Moderate diabetic retinopathy refers to tiny alterations in blood vessels that signal the beginning of a disorder. A comprehensive restoration is conceivable at this point. If correct treatment is not performed, this would proceed to mild diabetic retinopathy in a few years, causing blood vessel leaking. The illness then progresses to serious and proliferative diabetic retinopathy, which can result in total vision loss. A substantial amount of training phase information is required to forecast diabetic retinopathy with greater precision utilizing a machine learning approach. The information must originate from reputable organizations and be labelled correctly. EyePacs donated the Kaggle database that we utilized [19]. Greater than 1000 people were examined, and retinal photographs were captured by EyePacs. There are 654 photos for training and 346 for testing in the Kaggle database. The photos are ranging in dimension from 370 KB to 3 MB. Only a few photos, though, were under 550 KB. The Kaggle database is one of the most comprehensive collections of diabetic retinopathy photographs accessible today. The number of photos in every diabetic retinopathy categories in the training phase and testing phase databases is shown in Table 2. The Kaggle databases included photographs from various diabetic retinopathy classifications in one directory, as well as a CSV document with descriptions for every photograph classification. The photographs must be split and positioned in distinct files for training phase and testing phase. The photos were separated using a program depending on CSV identifiers, which is displayed here. To extract the primary elements, the photos were then reduced utilizing the Otsu technique [47]. A filtration technique was also used to equalise and alter the contrast of the photos. To boost the complexity of information, information augmenting was also

TABLE 4: The amount of photos for training phase and testing phase in every diabetic retinopathy (DR) category.

Diabetic retinopathy classification/photographs	Training phase		Testing phase	
	Right eye	Left eye	Right eye	Left eye
Regular (no diabetic retinopathy)	952	982	927	828
Mild diabetic retinopathy	231	323	875	905
Moderate diabetic retinopathy	695	813	910	860
Severe diabetic retinopathy	559	536	712	724
Proliferate diabetic retinopathy	466	464	721	697

TABLE 5: (a) Single assignment technique, (b) multiassignment technique, and (c) proposed technique Ap scores of DR associated characteristic identification.

Technique	CWS	Set of verifications			
		SRH	IRH	MA	HE
Single-assignment	1.7782	1.8731	1.9773	0.7591	1.9249
Multiassignment	0.7786	1.8725	0.9794	1.7548	0.9371
Proposed	1.7918	1.8945	1.987	0.7659	1.9272

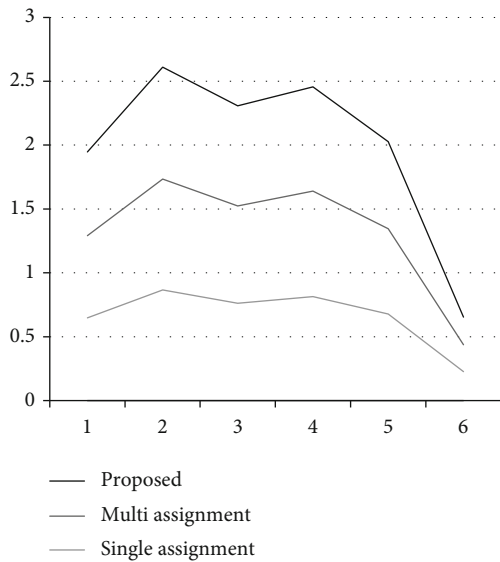


FIGURE 3: Proposed method comparison.

used. Cropping, flipping, and padding techniques were also carried out.

4.2. Evaluation of DR-Related Component Identification Effectiveness. Table 5 shows the findings of the proposed method’s diabetic retinopathy-associated component identification on the verification and 2 testing set, with an AP score assigned to every specific diabetic retinopathy-associated component. The averaged AP score is also provided in Table 5 to summarise the effectiveness of the suggested technique on the 12 characteristics within evaluation. Table 5 also shows the findings produced from single as well as multi approaches for comparability.

As could be shown, the suggested technique has the greatest mean AP score of 0.7578 among 12 characteristics for the validating collection, contrasted to 0.6063 for the multiassignment technique and 0.7176 for the single assign-

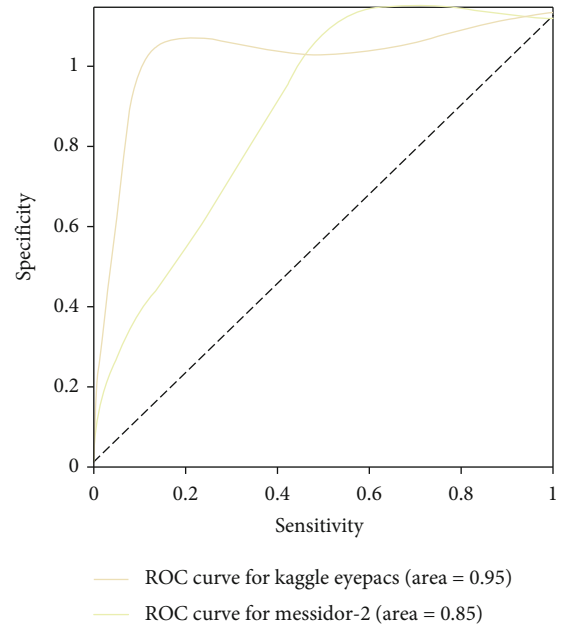


FIGURE 4: (AUC) for the replicated technique, the region underneath the receiver’s operational characteristic curves.

ment technique. The proposed technique obtains the greatest AP scores for 10 out of 12 specific attributes. Especially contrasted to the singular technique for the first five characteristics (in other words, the characteristics with balancing information in the validating collection), the suggested methodology produces considerably greater AP scores for characteristics CWS, IRH, and SRH; likewise, it outperforms the multiassignment technique for characteristics SRH and IRH.

The proposed methodology achieves the greatest mean AP values of 0.6086 between twelve characteristics, contrasted to 0.6680 for the multitask technique as well as 0.6789 for the single technique, in the testing 1 dataset. The suggested technique obtains the greatest AP scores for 7 out of 12 specific characteristics, contrasted to 3 for the

TABLE 6: Effectiveness on replica testing sets, comparable to the actual research's findings.

Testing datasets	High specificity	High sensitivity	Area under the ROC curve scores
KaggleEyePACS testing (actual EyePACS)	94.7 (92.4%)	95.7 (99.6)%	0.972 (1.095)
	95.1 (99.2)%	95.8 (95.5)%	

multitasking technique and two for the single assignment technique. The suggested strategy achieves considerably greater AP attributes for attributes CWS, MA, HE, and IRH when contrasted to the single technique, as well as considerably greater AP scores for characteristics HE, MA, SRH, and IRH, when contrasted to the single technique for the first 5 characteristics (in other words the characteristics with equitable information in the testing phase).

Furthermore, between the 11 characteristics in the testing dataset, the suggested technique has the least median AP score of 0.7628 (in this database, the characteristic TRD is not accessible). For the first five characteristics, meanwhile, it gets the greatest median AP score of 0.8391, comparing to 0.8318 for the multiassignment technique and 0.8267 for the single assignment technique (in other words the characteristics in the testing dataset with balanced values). Furthermore, whether contrasted to the single technique, the suggested methodology has considerably greater AP scores for elements HE, MA, SRH, and IRH, and much greater AP ratings for characteristic SRH while contrasted to the multiassignment technique.

We discovered that a patience of 15 epochs performed effectively for the initially terminating condition at a high AUC. AUC is greater than the prior highest values, with a minimal differential of 0.02. This was our condition for a higher maximum AUC. The effectiveness of the replicated method was assessed using two different testing datasets. In Figure 3, we summarise the variations in photograph distribution employed in our reproducing research with the initial research. On our KaggleEyePACS testing data collection as well as Messidor-2, our recreated technique had an AUC of 0.992 (97 percent CI, 1.958-1.967) and 1.964 (97 percent CI, 1.946-1.982), correspondingly (Figure 4 and Table 6). We see a significant difference among the AUC and the actual survey's AUC. Finally, we tried training with non-gradable photos excluded, however, this did not improve technique effectiveness.

**4.3. Discussion.** We developed two deep learning algorithms to forecast the onset of diabetic retinopathy within next 2 years and tested both on two databases: an inner validating collection of photos from mostly Hispanic individuals in the United States, and an exterior evaluation collection. The deep learning algorithm performed well on both databases, both in exclusion and when modified for hazard variables. When accessible hazard variables were integrated with them, the prognosis was better than when the hazard variables were used individually. The deep learning device's prognostication expanded to forecast incidence diabetic retinopathy after 2 years, as well as visual threatening diabetic retinopathy also mild diabetic retinopathy, according to Kaplan-Meier assessments. In the appendices, the discrepan-

cies in calibrating among the two verification datasets are examined.

Numerous techniques for categorising diabetic retinopathy hazard have been characterised, including employing specific hazard variables to minimise monitoring probability, predicting advancement to diabetic macular edema utilizing microaneurysm scoring percentage but also centre macular thickness, but also predicting occurrence diabetic retinopathy utilizing retinal arteriolar distension. A multifocal electroretinogram was also found to be able to forecast the establishment of novel retinopathy at particular retinal regions. Deep learning was also used on colour fundus pictures to forecast advancement on the initial therapy diabetic retinopathy research score by 2 or more levels. The research has several drawbacks, including the lack of an updated hazard component assessment, the lack of an external validating collection, the limited research sample (540 individuals), the usage of cross-validation as a result, and restricted inclusion requirements.

In various respects, our research advances earlier research. To begin, we look at the difficult problem of categorising individuals based on their chance of acquiring diabetic retinopathy using colour fundus photos and probability variables, both of which are readily accessible for many monitoring situations. By categorising the greatest category of individuals, those without any diabetic retinopathy at baseline, this technique immediately addresses the challenge of improving monitoring durations. Furthermore, despite accounting for existing hazard variables, our method still had a strong predictive accuracy. Third, we tested our method on two different verification samples from two different continents. Considering changes in patient demographics, glycated haemoglobin concentrations, fundus cameras, graded processes, and average occurrences, our approach kept significant predicting accuracy throughout both validating datasets. This conclusion shows the existence of delicate indications that are not visible to the naked eye, a phenomena that deserve more investigation. Third, while the major sector was determined to be the most relevant for predicting recurrent diabetic retinopathy, the temporally and nasal sectors were determined to be the finest combination. These findings could be reconciled by remembering that the major sector is made up of the temporal and nasal sectors, and that these two domains when merged offer a greater wide picture of the retinal. Furthermore, whenever the superior and inferior parts of the fundamental domain were eliminated, they had the lowest impact on deep learning algorithm predictive capability, implying that they were the lowest essential. In contrast, when the macular area is excised, it had the greatest impact and was also the more prognoses in solitude. As a result, the deep learning algorithm gave the macular and the retinal's peripheral equal weight in predications.

The optimization of screening frequencies could be one use of this deep learning technique. The earliest retinopathy is discovered, ever more efficient therapies, including such intravitreal doses and infrared photocoagulation of antivas-cular endothelial development factors. While conventional diabetic retinopathy testing depended on indirectly or directly slit lamp biomicroscopy or ophthalmoscopy, fundus photography's simplicity of usage, expense efficiency, and precision has resulted to its inclusion in a number of diabetic retinopathy monitoring recommendations. Medical hazard elements, resource accessibility (for example, scanning tech-nology, materials, and people), and other economic consid-erations all figure into the spectrum of testing periods in these recommendations (for example, 12 to 24 months for patients with no obvious diabetic retinopathy). Patients at higher haz-ard may also be worked up more regularly to guarantee ear-lier identification, while individuals at minimal hazard may be following up less regularly to decrease the monitoring bur-den experienced by individuals, physicians, and the medical systems. Individuals at the greatest hazard acquired diabetic retinopathy at a frequency of more than 90 percent in our research, while patients at the least hazard had a probability of getting diabetic retinopathy of fewer than 10 percent. Fur-thermore, additional research would require focusing on the particular cut-offs for determining higher and lower hazard category, as well as the corresponding treatments, which would most likely be adjusted to regional resources accessi-bility and practise structures.

## 5. Conclusion

A DRNN-deep recurrent neural network system for evaluat-ing colour fundus photographs for diabetic retinopathy identification is presented in this research. On the DRIVE datasets, the approach is tested effectively. With 95.6 percent precision, the suggested algorithm categorised healthy and harmful photos. With drastically minimised cross-entropy losses functional of 0.4356 the suggested model achieves the best precision efficiency. When compared current approaches to the traditional inception deep RNN approach, there is a 14.69 percent boost in efficiency. This research focuses on attributes relevancy and categorization strategies for effectively categorising diseases related to the retina using characteristics derived from retinal pictures via photograph processor approaches. The long-term objective of this study is to build lower expense technology capable of on-site real-time retina picture categorization. Because of the complexity of the proposed applications, the sensitivity (true negatives) must be near to 100 percent to minimise the dangers of a false categorization outcome. In particular, the device's sen-sitivities must be increased for a practical use in order to eliminate unwanted testing and correlated expenses.

## Data Availability

The data used to support the findings of this study are included within the article. Further data or information is available from the corresponding author upon request.

## Conflicts of Interest

The authors declare that there are no conflicts of interest regarding the publication of this paper.

## Acknowledgments

The authors appreciate the supports from MizanTepi Uni-versity, Ethiopia for the research and preparation of the manuscript. The authors thank Sri Indu College of Engineer-ing and Technology, Panimalar Engineering College, and Koneru Lakshmaiah Education Foundation for providing assistance to complete this work. This project was supported by Researchers Supporting Project number (RSP-2021/283) King Saud University, Riyadh, Saudi Arabia.

## References

- [1] D. S. Fong, L. Aiello, T. W. Gardner et al., "Retinopathy in diabet-es," *Diabetes Care*, vol. 27, suppl\_1, pp. s84-s87, 2004.
- [2] G. G. Yen and W.-F. Leong, "A sorting system for hierarchical grading of diabetic fundus images: a preliminary study," *IEEE Transactions on Information Technology in Biomedicine*, vol. 12, no. 1, pp. 118-130, 2008.
- [3] A. Tuulonen, P. J. Airaksinen, A. Montagna, and H. Nieminen, "Screening for glaucoma with a non-mydratic fundus cam-era," *Acta Ophthalmologica*, vol. 68, no. 4, pp. 445-449, 1990.
- [4] E. Stefánsson, T. Bek, M. Porta, N. Larsen, J. K. Kristinsson, and E. Agardh, "Screening and prevention of diabetic blind-ness," *Acta Ophthalmologica Scandinavica*, vol. 78, no. 4, pp. 374-385, 2000.
- [5] V. Elizabeth Jesi, S. Mohamed Aslam, G. Ramkumar, A. Sabarivani, A. K. Gnanasekar, and P. Thomas, "Energetic glaucoma segmentation and classification strategies using depth optimized machine learning strategies," *Contrast Media & Molecular Imaging*, vol. 2021, article 5709257, 11 pages, 2021.
- [6] T. Y. Wong, R. Klein, B. E. Klein, J. M. Tielsch, L. Hubbard, and F. J. Nieto, "Retinal microvascular abnormalities and their relationship with hypertension, cardiovascular disease, and mortality," *Survey of Ophthalmology*, vol. 46, no. 1, pp. 59-80, 2001.
- [7] M. D. Abràmoff, M. K. Garvin, and M. Sonka, "Retinal imag-ing and image analysis," *IEEE Reviews in Biomedical Engineer-ing*, vol. 3, pp. 169-208, 2010.
- [8] N. Patton, T. M. Aslam, T. MacGillivray et al., "Retinal image analysis: concepts, applications and potential," *Progress in Ret-inal and Eye Research*, vol. 25, no. 1, pp. 99-127, 2006.
- [9] X. Li, X. Hu, L. Yu, L. Zhu, C.-W. Fu, and P.-A. Heng, "CANet: cross-disease attention network for joint diabetic retinopathy and diabetic macular edema grading," *IEEE Transactions on Medical Imaging*, vol. 39, no. 5, pp. 1483-1493, 2020.
- [10] F. Li, Z. Liu, H. Chen, M. Jiang, X. Zhang, and Z. Wu, "Auto-matic detection of diabetic retinopathy in retinal fundus pho-tographs based on deep learning algorithm," *Translational Vision Science & Technology*, vol. 8, no. 6, pp. 4-4, 2019.
- [11] V. Gulshan, R. P. Rajan, K. Widner et al., "Performance of a deep-learning algorithm vs manual grading for detecting diabet-ic retinopathy in India," *JAMA Ophthalmology*, vol. 137, no. 9, pp. 987-993, 2019.

- [12] G. Ramkumar and E. Logashanmugam, "Study on impulsive assessment of chronic pain correlated expressions in facial images," *Biomedical Research*, vol. 29, no. 16, 2018.
- [13] T. D. Keenan, S. Dharssi, Y. Peng et al., "A deep learning approach for automated detection of geographic atrophy from color fundus photographs," *Ophthalmology*, vol. 126, no. 11, pp. 1533–1540, 2019.
- [14] S. Keel, P. Y. Lee, J. Scheetz et al., "Feasibility and patient acceptability of a novel artificial intelligence- based screening model for diabetic retinopathy at endocrinology outpatient services: a pilot study," *Scientific Reports*, vol. 8, no. 1, pp. 1–6, 2018.
- [15] S. Karthikeyan, G. Ramkumar, S. Aravindkumar, M. Tamilselvi, S. Ramesh, and A. Ranjith, "A novel deep learning-based black fungus disease identification using modified hybrid learning methodology," *Contrast Media & Molecular Imaging*, vol. 2022, article 4352730, 11 pages, 2022.
- [16] R. Sayres, A. Taly, E. Rahimy et al., "Using a deep learning algorithm and integrated gradients explanation to assist grading for diabetic retinopathy," *Ophthalmology*, vol. 126, no. 4, pp. 552–564, 2019.
- [17] C. Wilkinson, Ferris FL 3rd, R. E. Klein et al., "Proposed international clinical diabetic retinopathy and diabetic macular edema disease severity scales," *Ophthalmology*, vol. 110, no. 9, pp. 1677–1682, 2003.
- [18] D. Xiao, A. Bhuiyan, S. Frost, J. Vignarajan, M.-L. Tay-Kearney, and Y. Kanagasigam, "Major automatic diabetic retinopathy screening systems and related core algorithms: a review," *Machine Vision and Applications*, vol. 30, no. 3, pp. 423–446, 2019.
- [19] P. Vora and S. Shrestha, "Detecting diabetic retinopathy using embedded computer vision," *Applied Sciences*, vol. 10, no. 20, p. 7274, 2020.
- [20] M. Tamilselvi and G. Ramkumar, "Non-invasive tracking and monitoring glucose content using near infrared spectroscopy," in *2015 IEEE International Conference on Computational Intelligence and Computing Research (ICIC)*, pp. 1–3, Madurai, India, 2015.
- [21] C. Lam, D. Yi, M. Guo, and T. Lindsey, "Automated detection of diabetic retinopathy using deep learning," *AMIA summits on translational science proceedings*, vol. 2018, p. 147, 2018.
- [22] S. Mahesh and G. Ramkumar, "Smart face detection and recognition in low resolution images using Alexnet CNN compare accuracy with SVM," *Alinteri Journal of Agriculture Sciences*, vol. 36, no. 1, pp. 721–726, 2021.
- [23] R. Gargeya and T. Leng, "Automated identification of diabetic retinopathy using deep learning," *Ophthalmology*, vol. 124, no. 7, pp. 962–969, 2017.
- [24] N. Datta, R. Banerjee, H. Dutta, and S. Mukhopadhyay, "Hardware based analysis on automated early detection of diabetic-retinopathy," *Procedia Technology*, vol. 4, pp. 256–260, 2012.
- [25] J. Beagley, L. Guariguata, C. Weil, and A. A. Motala, "Global estimates of undiagnosed diabetes in adults," *Diabetes Research and Clinical Practice*, vol. 103, no. 2, pp. 150–160, 2014.
- [26] M. N. Ozieh, K. G. Bishu, C. E. Dismuke, and L. E. Egede, "Trends in health care expenditure in U.S. adults with diabetes: 2002–2011," *Diabetes Care*, vol. 38, no. 10, pp. 1844–1851, 2015.
- [27] L. Sellahewa, C. Simpson, P. Maharajan, J. Duffy, and I. Idris, "Grader agreement, and sensitivity and specificity of digital photography in a community optometry-based diabetic eye screening program," *Clinical Ophthalmology (Auckland, NZ)*, vol. 8, p. 1345, 2014.
- [28] L. Guariguata, D. R. Whiting, I. Hambleton, J. Beagley, U. Linnenkamp, and J. E. Shaw, "Global estimates of diabetes prevalence for 2013 and projections for 2035," *Diabetes Research and Clinical Practice*, vol. 103, no. 2, pp. 137–149, 2014.
- [29] M. R. K. Mookiah, U. R. Acharya, C. K. Chua, C. M. Lim, E. Ng, and A. Laude, "Computer-aided diagnosis of diabetic retinopathy: a review," *Computers in Biology and Medicine*, vol. 43, no. 12, pp. 2136–2155, 2013.
- [30] M. D. Abràmoff, Y. Lou, A. Erginay et al., "Improved automated detection of diabetic retinopathy on a publicly available dataset through integration of deep learning," *Investigative Ophthalmology & Visual Science*, vol. 57, no. 13, pp. 5200–5206, 2016.
- [31] R. J. Winder, P. J. Morrow, I. N. McRitchie, J. Bailie, and P. M. Hart, "Algorithms for digital image processing in diabetic retinopathy," *Computerized Medical Imaging and Graphics*, vol. 33, no. 8, pp. 608–622, 2009.
- [32] D. Sidibé, I. Sadek, and F. Mériaudeau, "Discrimination of retinal images containing bright lesions using sparse coded features and SVM," *Computers in Biology and Medicine*, vol. 62, pp. 175–184, 2015.
- [33] Y. Han, M. A. Bearnse, M. E. Schneck, S. Barez, C. H. Jacobsen, and A. J. Adams, "Multifocal electroretinogram delays predict sites of subsequent diabetic retinopathy," *Investigative Ophthalmology & Visual Science*, vol. 45, no. 3, pp. 948–954, 2004.
- [34] A. Bora, S. Balasubramanian, B. Babenko et al., "Predicting the risk of developing diabetic retinopathy using deep learning," *The Lancet Digital Health*, vol. 3, no. 1, pp. e10–e19, 2021.
- [35] Y. Han, M. E. Schneck, M. A. Bearnse Jr. et al., "Formulation and evaluation of a predictive model to identify the sites of future diabetic retinopathy," *Investigative Ophthalmology & Visual Science*, vol. 45, no. 11, pp. 4106–4112, 2004.
- [36] A. Sungeetha and R. Sharma, "Design an early detection and classification for diabetic retinopathy by deep feature extraction based convolution neural network," *Journal of Trends in Computer Science and Smart technology*, vol. 3, no. 2, pp. 81–94, 2021.
- [37] F. Arcadu, F. Benmansour, A. Maunz, J. Willis, Z. Haskova, and M. Prunotto, "Deep learning algorithm predicts diabetic retinopathy progression in individual patients," *NPJ Digital Medicine*, vol. 2, no. 1, pp. 1–9, 2019.
- [38] S. K. Somasundaram, "A machine learning ensemble classifier for early prediction of diabetic retinopathy," *Journal of Medical Systems*, vol. 41, no. 12, pp. 1–12, 2017.
- [39] V. Gulshan, L. Peng, M. Coram et al., "Development and validation of a deep learning algorithm for detection of diabetic retinopathy in retinal fundus photographs," *JAMA*, vol. 316, no. 22, pp. 2402–2410, 2016.
- [40] T. Araújo, G. Aresta, L. Mendonça et al., "DR|GRADUATE: uncertainty-aware deep learning-based diabetic retinopathy grading in eye fundus images," *Medical Image Analysis*, vol. 63, article 101715, 2020.
- [41] M. Voets, K. Møllersen, and L. A. Bongo, "Replication study: development and validation of deep learning algorithm for detection of diabetic retinopathy in retinal fundus photographs," 2018, <https://arxiv.org/abs/1803.04337>.



- [42] R. Kohavi, "A study of cross-validation and bootstrap for accuracy estimation and model selection," *Ijcai*, vol. 14, no. 2, pp. 1137–1145, 1995.
- [43] Y. LeCun, Y. Bengio, and G. Hinton, "Deep learning," *Nature*, vol. 521, no. 7553, pp. 436–444, 2015.
- [44] F. A. Gers, J. Schmidhuber, and F. Cummins, "Learning to forget: continual prediction with LSTM," *Neural Computation*, vol. 12, no. 10, pp. 2451–2471, 2000.
- [45] M. Golabbakhsh and H. Rabbani, "Vessel-based registration of fundus and optical coherence tomography projection images of retina using a quadratic registration model," *IET Image Processing*, vol. 7, no. 8, pp. 768–776, 2013.
- [46] O. Ronneberger, P. Fischer, and T. Brox, "U-net: convolutional networks for biomedical image segmentation," in *International Conference on Medical image computing and computer-assisted intervention*, pp. 234–241, Cham, 2015.
- [47] A. M. Omer and M. Elfadil, "Preprocessing of digital mammogram image based on otsu's threshold," *American Academic Scientific Research Journal for Engineering, Technology, and Sciences*, vol. 37, no. 1, pp. 220–229, 2017.